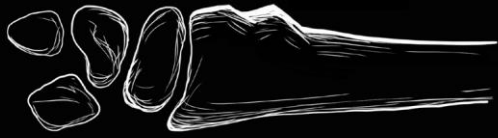



THE FORCE

PATHWAY


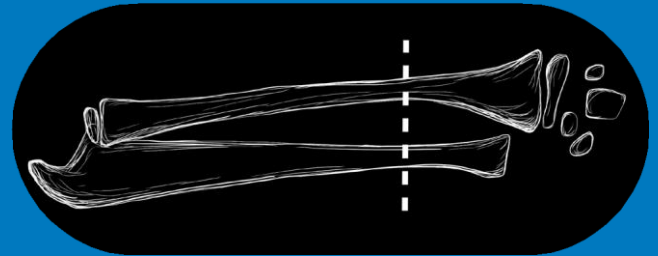


Is there an ISOLATED paediatric wrist fracture?

YES

YES

Is the fracture in the DISTAL 1/3 of the radius?
(with/without ulna fracture)



Is the cortex of the radius deformed (BUCKLED)?

YES

YES

Is the cortex INTACT all around the radius?
(i.e. no visible gap)



This is a BUCKLE fracture; Use the FORCE evidence:

- ✓ Offer a bandage/ splint
- ✓ Discharge without follow-up- DO NOT do a #clinic referral
- ✓ Give an information leaflet to take home

To see the published evidence and patient materials, go to
www.FORCEstudy.org