

LRI Emergency Department

Guideline for the management of:

Dental Injuries in Children

In the Paediatric Emergency Department (UHL Category C Guideline)

Staff relevant to: ED Medical and Nursing Staff

ED Guidelines Group: August 21st 2019

Version: 6

Trust Ref: C144/2016

Revision due: November 2025

Written by: J Bragg, S Green

Written by: J Bragg



DENTAL INJURIES IN CHILDREN

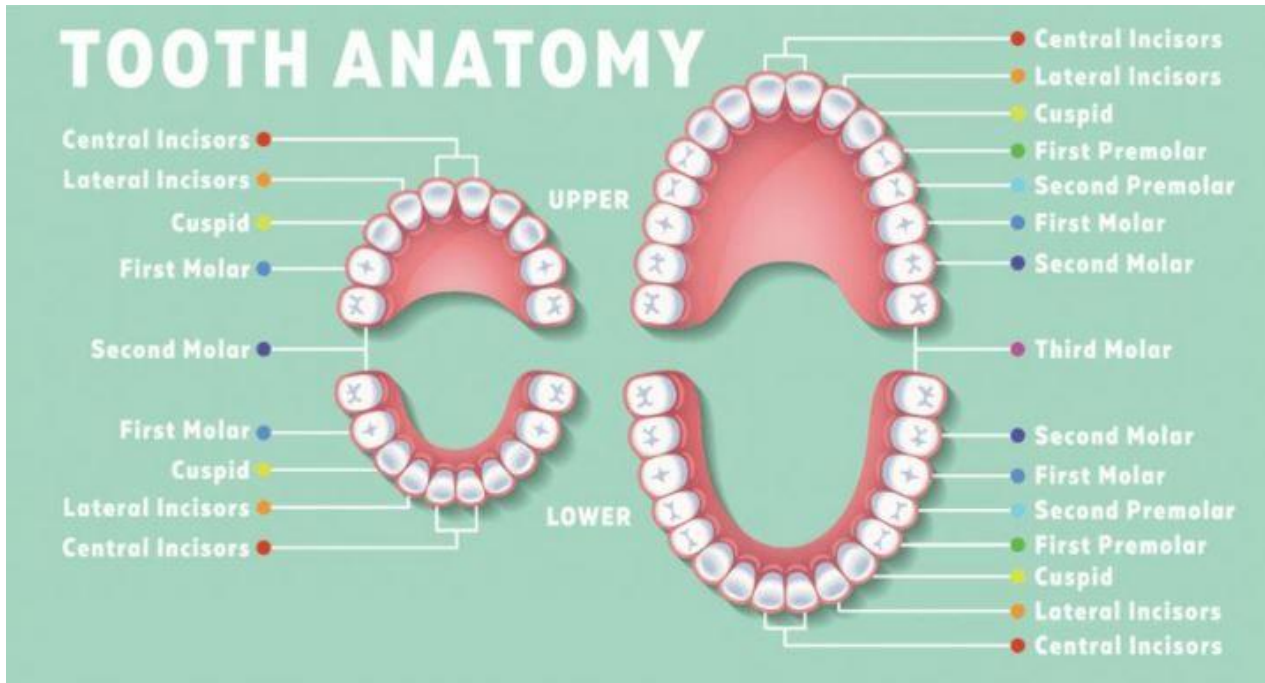
Dental Anatomy

Two complete sets of teeth

-primary (deciduous) (milk teeth): erupt between 6/12-2years

-permanent teeth begin to replace milk teeth at around 6 years

Anatomically there are four quadrants, with 8 permanent teeth per quadrant:



The injured tooth can be described accurately by the quadrant it is in and its position from the midline e.g. Upper L2 would mean the 2nd incisor in the left upper quadrant.

Types of Injury and their Management:

All tooth injuries should be managed ultimately by a dentist

Key points for A&E doctors

Maxfax team can be contacted via Nervecentre using the referral task.

I. BROKEN TOOTH:

- ✓ Where is the broken piece? Has it been aspirated? CXR to look for FB and / or ball-valve effect if history of choking or if unconscious (e.g. trauma call)
- ✓ Is the pulp exposed? This will be painful and will need referral.

II. BLEEDING TOOTH SOCKET:

Achieve haemostasis with pressure or if the child can, ask them to bite into wet gauze, soaked with adrenaline if necessary; call Max Fax

III. INTRUSION:

This term describes when incisor teeth have been pushed proximally into the gum after a trauma e.g. knocking upper incisors on a hard floor during a fall forwards

- ✓ Is there any other injury e.g. head or facial injury or intra/extra-oral laceration?
- ✓ Management depends on degree of intrusion, also intrusion of milk teeth often requires no immediate treatment: consult Max Fax on call, they may want an OPG

IV. AVULSED TOOTH:

- ✓ Primary (milk) teeth need not be replaced
- ✓ Permanent teeth should be re-implanted quickly, it is therefore important to ask the parent or guardian if this was a permanent tooth: **the prognosis for a re-implanted tooth worsens after 15mins, and it should therefore be replaced into the socket as soon as possible** and held in the mouth by biting down onto a wad of gauze until Max Fax arrive (**NB: Assessment Nurse should handover to a clinician ASAP as need priority for re-implants**)
- ✓ If handling the tooth, do so by the crown not the root.
- ✓ If immediate re-implantation is not possible (child can't co-operate) preserve tooth in cold milk or saliva, and refer to Max Fax as a priority.

V. DENTAL PAIN:

Refer to dentist / Maxfax depending on severity (caries vs abscess).
Emergency dentist can be contacted via 111 service.

Max Fax need to know if tooth is tender to percussion; facial swelling, fever, trismus, or dysphagia

Evidence shows that a high proportion of children presenting with dental injuries are a cause for child protection concerns (Thackeray et al 2007), this can be as much as 49% in infants and 38% of children (RCPCH 2017). It is imperative that all children are screened using the child protection prompt box below.

Children's ED Safeguarding Checklist		
	Yes	No
Is there a consistent history?		
Does the injury match the description of incident?		
Is the injury appropriate for the developmental stage of the child?		
Any delay in presentation has a satisfactory explanation?		
No other injuries/unexplained findings on examination?		
Are the parent/child interacting or behaving appropriately?		
If you answered NO to any of above OR are unsure, discuss the patient with the ED/Paeds Senior (ST4+)		

DISCHARGE CARE ADVICE CAN INCLUDE INFORMATION REGARDING:

- Mouth washes
- Dental hygiene
- Consulting their own dentist for follow up
- Soft diet
- Fluids.
- Pain relief.