

## **1. Introduction and Who Guideline applies to**

This guideline is intended for the use of clinicians who are involved in providing service to the paediatric and adolescent girls presenting with symptomatic or asymptomatic ovarian masses. The aim of this guideline is to fulfil the criteria of best service and best clinical practice which is evidence based and according to British Association of Paediatric and Adolescent Gynaecologist (BritSPAG) and RCOG.

The guideline does not include management of antenatally diagnosed or neonatal cysts as these will be managed by the team of the experts.

### **Background:**

Ovarian cysts in children are very common; the vast majority of them are benign and self-resolving, with less than 10% of these cysts being malignant <sup>[1]</sup>. Ovarian malignant tumours account for only 1% of all childhood cancers <sup>[2]</sup>. The management of ovarian cysts in children and adolescents should include the participation of a gynaecologist with a specialist knowledge of paediatric and adolescent gynaecology to reduce the over treatment of benign ovarian cysts which may resolve spontaneously. Any surgery for ovarian cysts should be carried out by a gynaecologist with the appropriate surgical skills to reduce the need for an unnecessary laparotomy or oophorectomy. Ovarian torsion is one of the only indications for immediate surgery and any other pathology can usually be discussed with a paediatric and adolescent gynaecologist prior to surgery.

When considering a differential diagnosis of adnexal pelvic masses, one must have a broad understanding of the physiological and pathological processes that are likely to occur within the pelvis and abdomen. Adolescents particularly pose a challenge when it comes to pelvic organs as their physiology is rapidly changing and often the distinction between pathology and physiology is difficult, hence a multidisciplinary approach with Paediatric Surgeons, Radiology and Gynaecology is the safest way forward. Occasional involvement of other specialists may be required in specific cases.

## **2. Guideline Standards and Procedures**

### **Recommendation One:**

Correct definition is to be used for diagnosis and planning the treatment. Ovarian cysts can be simple or complex.

A cyst is a fluid filled sac which is greater than 5cm and so a 'cyst' which is less than 5cm should not be classified as a cyst, it is a normal physiological occurrence, unless the child has not yet achieved menarche.

A simple ovarian cyst is one which is unilocular and fluid filled, with no septations, solid areas or other features. Simple cysts are most often a normal physiological finding which occurs due to the menstrual cycle. If no egg is released from a developing follicle, the fluid stays in the follicle and forms a cyst this is called a follicular cyst. If the egg has been released a corpus luteum cyst can form and this type of cyst often contains a small amount of blood.

A complex cyst can be multilocular and will contain solid areas; examples include endometriomas and dermoid cysts. Complex cysts can have features suspicious of malignancy.

**Recommendation Two:**

Suitable imaging should be sought. Ultrasound (USS) is the initial radiological investigation of choice.

USS should be performed preferably by a radiologist or radiographer with experience in paediatric gynaecological imaging. This should be performed trans-abdominally in girls who have not been sexually active. In cases of complex cysts, ultrasound documentation of size of solid components along with features of vascularity or enhancement in papillary projection would be useful in Calculation of RMI.

**Recommendation Three:**

A sexual history should be asked irrespective of age.

In the sexually active adolescent it is essential that pregnancy, ectopic pregnancy and tubo-ovarian masses secondary to pelvic inflammatory disease (PID) are considered in the differential diagnosis of abdominal pain and mass lesions in the pelvis. The emergency gynaecology team would help with appropriate management of these adolescents with adult problems.

**Recommendation Four:**

Further investigations may need to be considered depending upon the size and nature of the cyst.

In the acute setting, for example if an ovarian torsion is clinically suspected then the patient may need to go to theatre prior to further investigations. An USS in a pre-pubescent ovarian torsion will often show peripherally arranged follicles in addition to ovarian enlargement and oedema [4].

In the non-acute setting, if the child/adolescent has achieved menarche then the following investigations apply [3, 5, 8];

- If the cyst is complex or there are any suspicious features, germ cell tumour markers (HCG, AFP, LDH, CEA) and CA125 should be performed.
- An MRI may also be considered.

If an ovarian cyst is found in a pre-pubertal girl, the following investigations should be considered especially if there are any signs of precocious puberty;

- Hormone profile (including FSH, LH, oestradiol and thyroid function).

**Recommendation Five:**

Complex cysts can be either benign or malignant. For all complex cysts, tumour markers are required. It is ideal to discuss management of complex, suspicious appearing cysts in the gynaecological oncology/paediatric oncology settings.

Any child or young person in whom there is a suspicion of malignancy must be discussed in the regional paediatric solid tumour MDT and must have their surgery in Nottingham according to the pathway.

This is obviously not the case in an emergency situation as we would not want to delay surgery in those circumstances.

**Benign complex cysts**

- Endometrioma

Pelvic mass arising from growth of ectopic endometrial tissue within the ovary, typically contain thick brown fluid, commonly referred to as a chocolate cyst.

Pain is usually cyclical and may be associated with dysmenorrhoea and dyspareunia (if sexually active).

- Dermoid (Mature cystic teratoma)

These are the most common benign tumours in children and adolescents. They tend to grow slowly and contain mature tissue. They can frequently contain clumps of hair, pockets of sebum, blood, fat, bone, nails, teeth, eyes, cartilage and thyroid tissue. They have a classical appearance on ultrasound and MRI.

- Haemorrhagic cyst

These usually result from haemorrhage into a corpus luteum or other functional cyst. Radiographic features are variable depending on the age of the haemorrhage and may mimic an endometrioma. A rescan will often eliminate confusion as a haemorrhagic cyst will usually resolve over a 2-3 cycles, but endometrioma usually will not resolve in the absence of treatment.

### Malignant

Germ cell tumours are the most common malignancy

- Dysgerminoma
- Endodermal sinus tumour (usually associated with a rise in AFP)
- Embryonal carcinoma
- Choriocarcinoma (associated with a rise in hCG)

### Recommendation Six:

A conservative approach is appropriate for asymptomatic simple ovarian cysts which are 5-7cm.

A conservative approach is appropriate for asymptomatic simple ovarian cysts which are 5-7cm; these can be followed up with an annual USS [4] and the patient should be referred to the Paediatric and Adolescent Gynaecology clinic to review the follow up ultrasound scan and organise on-going management. Cysts that persist or increase in size are unlikely to be functional and may warrant surgical management and the patient should be referred to the paediatric and adolescent gynaecology clinic to decide upon further management. Any cyst which is simple and less than 5cm, does not require any follow up unless the child has not yet achieved menarche.

Girls who have not yet achieved menarche should be discussed with a paediatric gynaecologist regardless of the size of the cyst.

### Recommendation Seven:

Surgery may be performed in symptomatic patients although there is no evidence-based consensus on the optimal size of the cyst. Laparoscopy is the preferred route of surgery.

There is no evidence-based consensus regarding which sized cysts are suitable to surgery. However, most studies performed in premenopausal women have used an arbitrary maximum diameter to 50-60mm among their inclusion criteria to offer conservative management [8].

The management of all adolescents with an ovarian cyst should ideally be discussed with the gynaecology team prior to any surgical management.

If an ovarian cyst is identified incidentally as the time of non-gynaecological surgery, a gynaecologist should be informed prior to embarking on any surgery on the ovarian cyst. A paediatric surgeon should also be involved in cases involving younger children. If malignancy is suspected, the case should be discussed within a gynaecological or paediatric oncology multidisciplinary team.

Laparoscopic surgery (as opposed to laparotomy) is preferred as it will reduce post-operative pain, length of hospital stay and reduce adhesion formation post-operatively [4].

Whichever method of surgery is chosen, every attempt should be made to save the ovary and perform a cystectomy rather than an oophorectomy. In children, preservation of as much ovarian tissue as possible is desired. This is especially important for pubertal development as well as for future fertility.

Cystectomy is the operation of choice as drainage alone is associated with a high chance of reoccurrence and is therefore not recommended [4]. This is particularly important for endometrioma cysts, as cystectomy has not only proven to reduce the risk of reoccurrence but also reduce pelvic pain when compared to drainage [7]. The management of endometriomas are best performed in association with an endometriosis centre [7].

Laparoscopic cystectomy is also the treatment of choice for dermoid cysts/teratoma to preserve ovarian function. Any inadvertent spillage intraoperatively should be efficiently cleared up with thorough irrigation and suctions, with careful attention to the paracolic gutters as the risk of chemical peritonitis is less than 1% [8].

Teratomas, dermoid cysts and endometriomas are conditions which can represent and occur bilaterally. Therefore, preservation of ovarian tissues is essential, in case future surgery is required whereby the subsequent cyst presents on their contralateral ovary.

In ovarian torsion every effort should be made to save the ovary by untwisting the ovary and draining any cysts. A consultant with the relevant expertise should be involved. Even if the ovary appears black and necrotic in most cases the ovary will usually recover and result in a functional ovary [9]. Cystectomy would be difficult in this situation due to the fragile tissues and can be carried out at an interval operation if required. Oophoropexy remains controversial with limited long term data and is generally not recommended [4].

#### **Recommendation Eight:**

The paediatric team are recommended to initiate basic investigations and liaise with a paediatric gynaecologist.

As these young girls are most likely to present to the paediatric department, it is recommended that the paediatric team organise the basic investigations that they may think are necessary and liaise with a paediatric gynaecologist as suggested.

In the event of non-availability of the Paediatric Gynaecologist and in emergency situations the emergency cover Gynaecologist based at the Gynaecology Assessment Unit (GAU) at LRI should be contacted for advice.

In circumstances where there is a suspicion of malignancy a direct involvement of the Gynaecology Oncologist based at LGH should be sought.

These patients, when admitted will need to be cared for in the paediatric ward due to their age and the facilities available for support of the parents that are likely to accompany them. It is required that the basic care be provided by the paediatric team including ordering of investigations, venous access, pain relief and fluid management as the paediatric team i.e. paediatric doctors and nurses have a greater familiarity with this aspect of care in the adolescent population. Booking theatre for surgery would need to be co-ordinated between the operating surgeons.

#### **Recommendation Nine:**

Follow up may be required.

Follow up is required in the following;

- All adolescent patients cared for by the multidisciplinary team should be invited for a follow up appointment in 6-8 weeks in the joint paediatric gynaecology clinic

The appointment for the paediatric/adolescent gynaecology clinic when on-going review and treatment is planned are accessed through the Orange team.

Contact numbers for gynaecology:

- GAU: Ext 16305
- Paediatric Gynaecology Secretary: Ext 17898
- Paediatric Gynaecology appointments: Orange team

### **3. Education and Training**

No definitive training or education is required for implementation of this guideline.

### **4. Monitoring Compliance**

<b>What will be measured to monitor compliance</b>	<b>How will compliance be monitored</b>	<b>Monitoring Lead</b>	<b>Frequency</b>	<b>Reporting arrangements</b>
Identification, referral and outcome of newly diagnosed ovarian cysts in paediatric/adolescent population	Medical record keeping and results from ICE	Miss Asmita Patwardhan	Yearly	Audit/Service evaluation, retrospective data collection
Tumour marker accuracy .vs. histology	Results from ICE	Miss Asmita Patwardhan	Yearly	Audit/Service evaluation, retrospective data collection

### **5. Supporting References**

- Kozlowski K.J ovarian masses. *Adolesc med* 1999; 10(2):337-350.
- Stephanian McConn DE. Gynaecological malignancies in adolescents. *Adolescent med clin.* 2004;15(3); 549-568.
- Deligeoroglou E ovarian masses during adolescence; clinical ultrasonographic and pathological findings. *Gynae endocrinology* 2004;19(1);1-8
- Damigos E, Johns J, Ross J. An update on the diagnosis and management of ovarian torsion. *The Obstetrician & Gynaecologist* 2012;14: 229–236
- Powell JK. Benign adnexal masses in the adolescent. *Adolescent med clin.* 2004; 15(3); 535-547.
- Cassandra M Kelleher. Adnexal masses in children and adolescents. *Clinical Obs and gynaecology* 58(1) December 2014
- Ovarian Masses in Premenopausal Women, Management of Suspected (Green-top Guideline No. 62), RCOG 2011
- Guideline for the management of ovarian cysts in children and adolescents, The British Society for Paediatric & Adolescent Gynaecology, December 2018

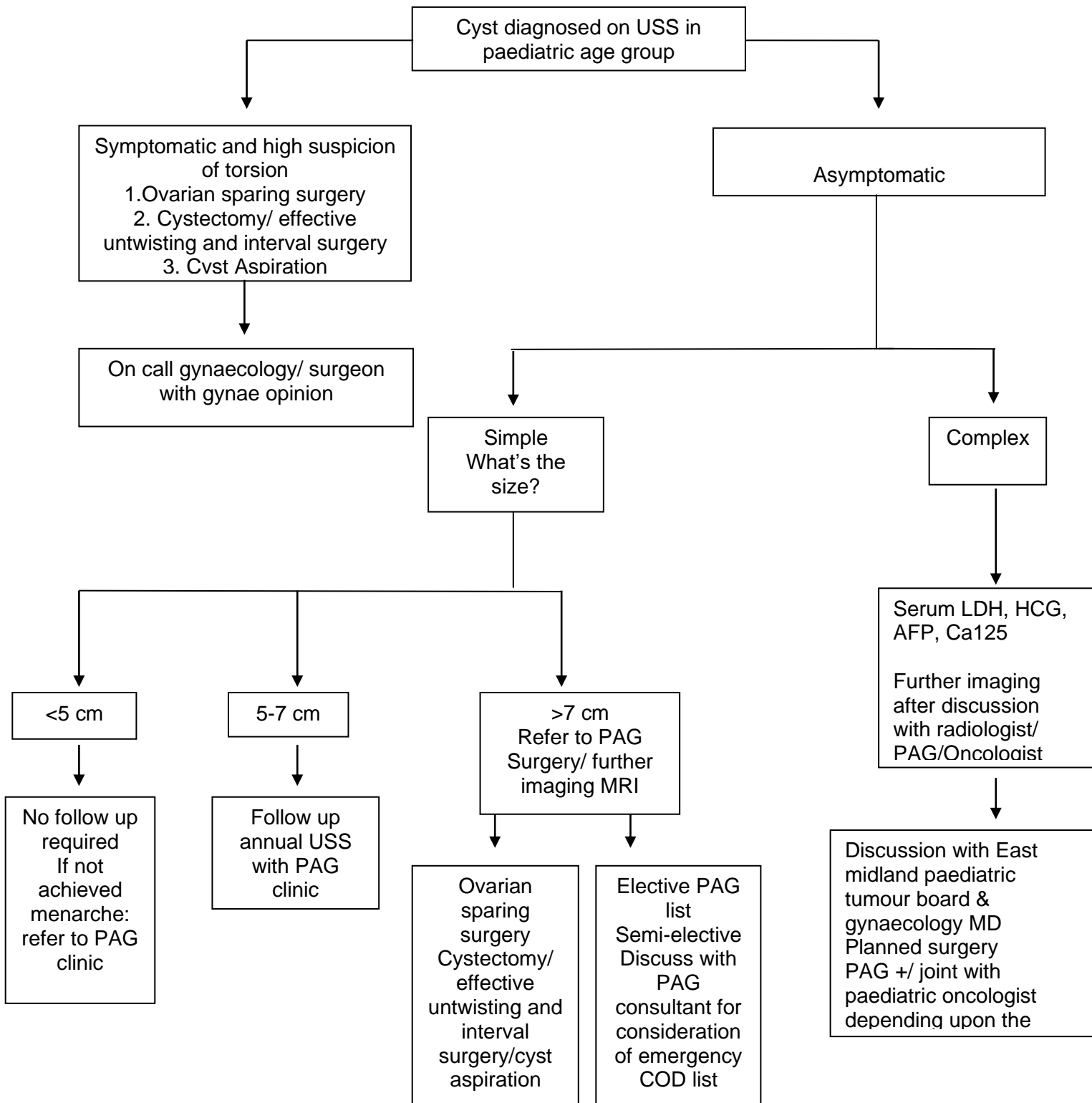
### **6. Key Words**

Ovarian Mass, Adolescents, Paediatric

The Trust recognises the diversity of the local community it serves. Our aim therefore is to provide a safe environment free from discrimination and treat all individuals fairly with dignity and appropriately according to their needs. As part of its development, this policy and its impact on equality have been reviewed and no detriment was identified.

DEVELOPMENT AND APPROVAL RECORD FOR THIS DOCUMENT			
<b>Author / Lead Officer:</b> Miss Asmita Patwardhan		<b>Executive Lead:</b> Chief Medical Officer	
REVIEW RECORD			
Date	Issue Number	Reviewed By	Description Of Changes (If Any)
November 2020	1		New document
April 2024	2	A Patwardan Consultant Gynaecologist E Ross Consultant Paediatric Oncologist Mr Nitin Patwardhan Consultant Paediatric Surgeon Head of Service Children's Surgery Savitha Shenoy – Consultant Paediatrician	Added ; Any child or young person in whom there is a suspicion of malignancy must be discussed in the regional paediatric solid tumour MDT and must have their surgery in Nottingham according to the pathway. This is obviously not the case in an emergency situation as we would not want to delay surgery in those circumstances.

## Ovarian Cyst Pathway



If an ovarian cyst is discovered incidentally at the time of surgery by a non-gynaecology speciality, please seek advice from the gynaecology team before commencing any intervention on the ovarian cyst.