

# LRI Emergency Department and Children's Hospital

## Preseptal and Orbital Cellulitis UHL Childrens Hospital Guideline

Staff relevant to:	Clinical staff working within the Children's Hospital and Emergency Department.
Team approval date:	July 2023
Version:	8
Revision due:	July 2026
Written by:	Aslam, Willmott, Woodruff S
Reviewed by:	Koo & R Radcliffe
Trust Ref:	D5/2020



### Contents

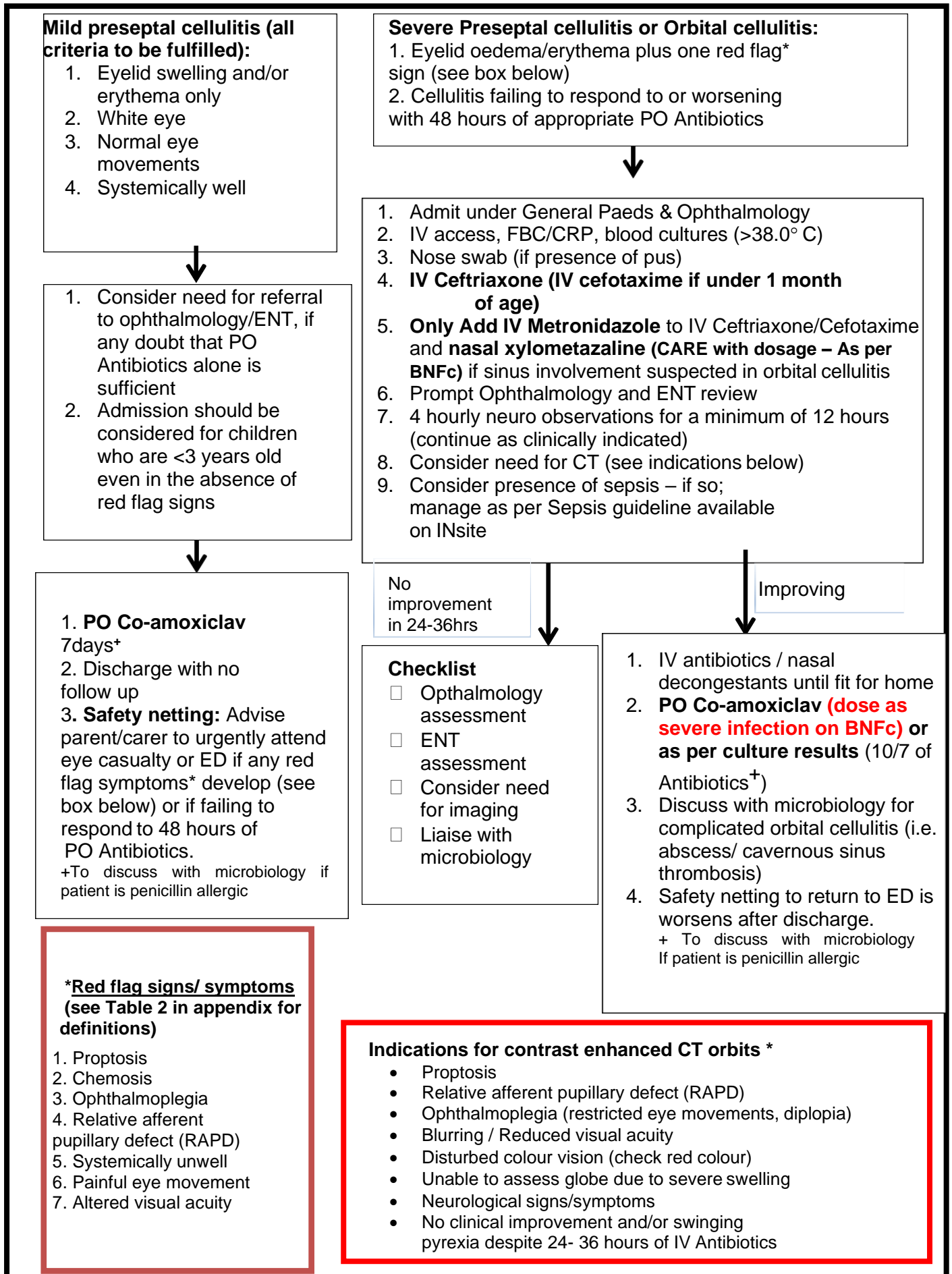
1. Introduction and Who Guideline applies to.....	1
2. Management of Children with Preseptal and Orbital Cellulitis .....	2
2.2 Background.....	3
Table 1:Pathogenesis & Clinical findings.....	3
3. Education and Training.....	4
4. Monitoring Compliance .....	4
5. Supporting Documents and Key References .....	4
6. Key Words.....	4
Contact and review details .....	5
Appendix 1: Table 2: Definition of red flag signs/symptoms.....	6
Appendix 2: Chandler's classification .....	6

### 1. Introduction and Who Guideline applies to

Periorbital infections are infections involving the soft tissues surrounding the globe of the eye. Chandler's classification has been used to describe periorbital infections (see appendix Table 3). The term 'periorbital cellulitis' encompasses both preseptal and orbital cellulitis.

This guideline is for the use of clinical staff working within the Children's Hospital and Emergency Department admitting/treating children presenting with suspected or confirmed cases of preseptal or orbital cellulitis. If the child is known to be immunocompromised, early discussion with microbiology is recommended as empiric choice of antimicrobials will be different.

## 2. Management of Children with Preseptal and Orbital Cellulitis



## Related documents

- [Neurological Observation Following Minor Head Injury UHL Childrens Nursing Guideline C1/2010](#)
- [Sepsis UHL Childrens Hospital Guideline B31/2016](#)

## 2.2 Background

**Preseptal cellulitis** is defined as infection anterior to the orbital septum. The orbital septum is a layer of fibrous tissue that arises from the periosteum of the skull and continues into the eyelids. This provides an effective barrier against the spread of infection from the preseptal tissues into the orbit. Preseptal cellulitis is much more common in children and is generally associated with more favourable outcomes. Preseptal tissues may be infected as a result from trauma (ie. insect bites, scratches), upper respiratory tract infection, or contiguous spread from adjacent tissues (ie. conjunctivitis, blepharitis, dacryocystitis). The most common causative organisms are *Strep pyogenes* (Group A Streptococci), *Staph aureus*, *Strep pneumoniae*, and *H. influenzae*.

**Orbital (postseptal) cellulitis** occurs when the infection has breached or located posteriorly to the orbital septum. It usually arises from a secondary spread from adjacent paranasal sinusitis particularly the ethmoid sinus but can rarely follow penetrating trauma, haematogenous spread or eye surgery. Orbital cellulitis may be complicated by the development of subperiosteal abscess, orbital abscess or cavernous sinus thrombosis. Orbital cellulitis is an ocular emergency and occurs more commonly in older children. It can be caused by Streptococcus spp (*Strep milleri*, *Strep pyogenes*, *Strep pneumoniae*), anaerobes and *H. influenzae*. *H. influenzae* type b is now uncommon with the routine childhood Hib immunisation. Suspected orbital cellulitis should be imaged by CT orbits (post contrast).

\*Post optic nerve involvement and cavernous sinus thrombosis as well as subperiosteal abscesses and para nasal sinus disease are delineated by this scan sequence and a CT head/brain is not required.

Immunocompromised children may be infected with more unusual pathogens such as fungi and other gram negative bacilli such as *Pseudomonas aeruginosa*. If the child is known to be immunocompromised, early discussion with microbiology is recommended as empiric choice of antimicrobials will be different.

**Table 1: Pathogenesis & Clinical findings**

	<b>Preseptal cellulitis</b>	<b>Orbital (postseptal) cellulitis</b>
<b>Pathogenesis</b>	Lid trauma, contiguous spread from adjacent tissues, conjunctivitis, blepharitis, dacryocystitis, bacteraemia	Sinusitis, trauma/ocular surgery, bacteraemia
<b>Clinical findings</b>	Erythematous/swollen lid and/or surrounding eye tissues Normal vision, no RAPD, extra-ocular movements full and painless, no proptosis Fever may be present but is usually mild and child is systemically well	Erythematous and swollen lid and surrounding tissues Eye pain, proptosis, chemosis, ophthalmoplegia, impaired visual acuity, painful eye movements Most have fever and usually systemically unwell

### **3. Education and Training**

This guideline will be available on INsite for access to staff working in paediatric ED and Children's Hospital.

### **4. Monitoring Compliance**

<b>What will be measured to monitor compliance</b>	<b>How will compliance be monitored</b>	<b>Monitoring Lead</b>	<b>Frequency</b>	<b>Reporting arrangements</b>
100% appropriate use of antibiotics according to the guideline	Review of case notes/ICE documentation	Paediatric or Microbiology team	3 yearly	Departmental Audit Meeting
100% prompt ENT and ophthalmology review in suspected orbital cellulitis cases	Review of case notes documentation	Paediatric, ENT or Ophthalmology team	3 yearly	Departmental Audit Meeting

### **5. Supporting Documents and Key References**

1. Durand ML. Periocular infections. Mandell, Douglas and Bennett's Principles and Practice of Infectious Diseases, 8<sup>th</sup> edition. Philadelphia: Elsevier, 2015: 1432-8 [Chapter 118].
2. Howe L and Jones NS. Guidelines for the management of periorbital cellulitis/abscess. Clin Otolaryngology. 2004; 29(6):725-8.
3. Watts P. Preseptal and orbital cellulitis in children: a review. Paediatric and Child Health 2011; 22(1):1-8.
4. Baring, D.E.C. & Hilmi, O.J. An evidence based review of Periorbital Cellulitis. Clin. Otolaryngol. 2011, 36, 57–64.
5. A V Mathew et al. Paediatric post-septal and pre-septal cellulitis: 10 years' experience at a tertiary-level children's hospital. BJR 2013, 87 (1033).
6. Chandler JR, Langenbrunner DJ, Stevens ER. The Pathogenesis of Orbital Complications in Acute Sinusitis. Laryngoscope 1970; 80: 1414-1428.
7. Fever in under 5s: assessment and initial management  
NICE guideline [NG143]Published: 07 November 2019 Last updated: 26 November 2021

### **6. Key Words**

Preseptal, Orbital, Cellulitis, Paediatrics

---

**The Trust recognises the diversity of the local community it serves. Our aim therefore is to provide a safe environment free from discrimination and treat all individuals fairly with dignity and appropriately according to their needs.**

**As part of its development, this policy and its impact on equality have been reviewed and no detriment was identified.**

Contact and review details			
Guideline Lead (Name and Title): Sharon Koo – Consultant Microbiologist Ruth Radcliffe – Consultant Paediatrician		Executive Lead: Chief Medical Officer	
REVIEW RECORD			
Date	Issue Number	Reviewed By	Description Of Changes (If Any)
	1	Aslam, Willmott, Woodruff	
Feb 2001	2	A Sridhar Woodruff	
Sept 2006	3		
2009	4		
June 2016	5	V Rai R Radcliffe C Wighton	
March 2017	6	S Koo R Radcliffe T Valsamakis A Tandon J Burns A BerryBrincat	<ul style="list-style-type: none"> <li>• Major text additions to background</li> <li>• Additions to table 1 pathogenesis &amp; clinical findings.</li> <li>• Removal of Bacteria in table 1</li> <li>• Addition of management flow chart</li> <li>• Addition of red flag definitions and classification tables in appendix</li> <li>• Updated reference list</li> </ul>
May 2020	7	S Koo R Radcliffe	<ul style="list-style-type: none"> <li>• Specified nasal decongestant.</li> <li>• Removed open access to CAU, as no longer available.</li> </ul>
May 2023	8	S Koo R Radcliffe	<p>Severe pathway – added that a nose swab is only indicated in the presence of pus. Also added to continue 4 hrly neuro obs for minimum of 12 hrs (continue as clinically indicated)</p> <p>Suspected orbital cellulitis should be imaged by CT orbits (post contrast). *Post optic nerve involvement and cavernous sinus thrombosis as well as subperiosteal abscesses and para nasal sinus disease are delineated by this scan sequence and a CT head/brain is not required. . If the child is known to be immunocompromised, early discussion with microbiology is recommended as empiric choice of antimicrobials will be different. addition of immunosuppressed patients under 'who this guideline applies to' addition of dose as per severe infection as perBNFc for PO co-amox stepdown for severe pre-septal or orbital cellulitis.</p>

## Appendix 1: Table 2: Definition of red flag signs/symptoms

Proptosis	Bulging of the eye anteriorly out of the orbit
Chemosis	Swelling (or oedema) of the conjunctiva
Ophthalmoplegia	Paralysis or weakness of the eye muscle(s)
Relative afferent pupillary reflex (RAPD)	A medical sign observed during the swinging-flashlight test whereupon the patient's pupils constrict less (therefore appearing to dilate) when a bright light is swung from the unaffected eye to the affected eye.
Systemically unwell	A child with systemic signs of infection (ie. fever >38 C or <36 C and abnormal observations). Under 5 years old: The child is considered to be systemically unwell if they have any red or amber symptoms or signs on the NICE 'traffic light' system (refer to NICE guidelines CG160)

## Appendix 2: Chandler's classification

### **Chandler et al. Periorbital Classification**

1. Pre-septal cellulitis
2. Orbital cellulitis
3. Sub-periosteal abscess
4. Orbital abscess
5. Cavernous sinus thrombosis